

Case Report

Management of pyogenic granuloma mimicking a tooth: A case report

Rakesh Kumar Yadav¹, Niharika Singh¹, Nishi Singh¹, Promila Verma¹

¹Department of Conservative Dentistry & Endodontics, King George's Medical University, Lucknow, Uttar Pradesh, India.

ABSTRACT

Pyogenic granuloma gravidarum is a benign, pregnancy-associated, reactive vascular lesion of the gingiva with a marked tendency to bleed. Surgical management can be challenging because of its high vascularity, especially in pregnant patients. A 37-year-old woman in her second trimester of pregnancy presented with a rapidly enlarging, bleeding, tooth-like gingival mass in the left maxillary posterior region that interfered with mastication and oral hygiene. Clinical and radiographic evaluations suggested a reactive gingival lesion. The lesion was excised using a 445 nm visible blue diode laser under local anesthesia. Histopathological examination confirmed the diagnosis of a pyogenic granuloma. Laser excision provided excellent intraoperative hemostasis, eliminated the need for sutures, and resulted in minimal postoperative discomfort. Healing was uneventful, with complete epithelialization within one week and no recurrence during the follow-up period. Excision of pyogenic granuloma gravidarum using a 445 nm visible blue diode laser achieved precise tissue removal, effective hemostasis, and favorable healing without the need for sutures. This technique may offer advantages in managing highly vascular lesions during pregnancy.

Keywords: Gingival diseases, Laser, Oral surgical procedures, Pregnancy complications, Pyogenic granuloma

INTRODUCTION

Pyogenic granuloma gravidarum is a benign, reactive, vascular lesion commonly associated with pregnancy due to hormonal influences that enhance angiogenesis and inflammatory responses. Clinically, it presents as a rapidly growing, erythematous, and highly vascular mass that frequently bleeds with minor provocation, causing discomfort and functional difficulties for the patient. The lesion was first described by Hullihen in 1844.^[1] Pyogenic granuloma is also known by several other terms, including granulation tissue-type hemangioma, granuloma gravidarum, lobular capillary hemangioma, pregnancy tumor, and eruptive hemangioma.^[2] The lesion most frequently affects the gingiva and is characterized by rapid growth, erythematous appearance, and a pronounced tendency to bleed.^[3,4] Although these lesions may regress after delivery, intervention is often required in cases of persistent bleeding, pain, interference with mastication, or rapid enlargement. Conventional management typically

involves scalpel excision; however, this approach may be associated with excessive bleeding, postoperative discomfort, and the need for suturing of the wound. These concerns are particularly relevant in pregnant patients.^[5,6,7] Laser-assisted excision has emerged as a minimally invasive alternative, offering superior hemostasis, reduced operative time, and improved patient comfort. This case report describes the successful management of pyogenic granuloma gravidarum using a 445 nm visible blue diode laser and highlights its clinical advantages and favorable healing response with the CARE guidelines.^[8]

CASE REPORT

Patient information

A 37-year-old pregnant woman (approximately 30 weeks of gestation) reported to the Department of Conservative Dentistry and Endodontics with a progressively enlarging gingival growth over a period of approximately 6-8 weeks, associated with intermittent bleeding during mastication and

*Corresponding author: Nishi Singh, Department of Conservative Dentistry & Endodontics, King George's Medical University UP, Lucknow, Shah Mina Rd, Chowk, Lucknow, Uttar Pradesh, India. drnishisingh@kgmcindia.edu

Received: 20 January 2026 Accepted: 23 February 2026 Published: 01 April 2026 DOI: 10.25259/JHRE_5_2026

This is an open-access article distributed under the terms of the Creative Commons Attribution-Non Commercial-Share Alike 4.0 License, which allows others to remix, transform, and build upon the work non-commercially, as long as the author is credited and the new creations are licensed under the identical terms.

©2026 Published by Scientific Scholar on behalf of Journal of Healthcare Research and Education.

tooth brushing. There was no history of similar lesions, systemic illness, trauma to the area, or relevant drug use. The lesion gradually increased in size without spontaneous regression.

Clinical examination revealed a solitary, exophytic, erythematous, nodular lesion measuring approximately 9.0 × 11.0 mm, with a smooth surface, soft-to-firm consistency, and a tendency to bleed on provocation. Oral hygiene was poor. Her medical, drug, and family histories were unremarkable. The chronological sequence of clinical events and management is summarized in Table 1.^[9]

Clinical findings

Intraoral examination revealed a dark red, elongated oval, pedunculated gingival mass measuring approximately 9 × 11 mm on the buccal aspect of the maxillary left posterior gingiva, extending from the marginal and interdental gingiva with respect to the maxillary left second molar (27). The lesion was soft to firm in consistency, non-tender, and bled easily upon probing. Notably, the growth exhibited a tooth-like appearance that mimicked the contour of an erupted tooth [Figure 1].

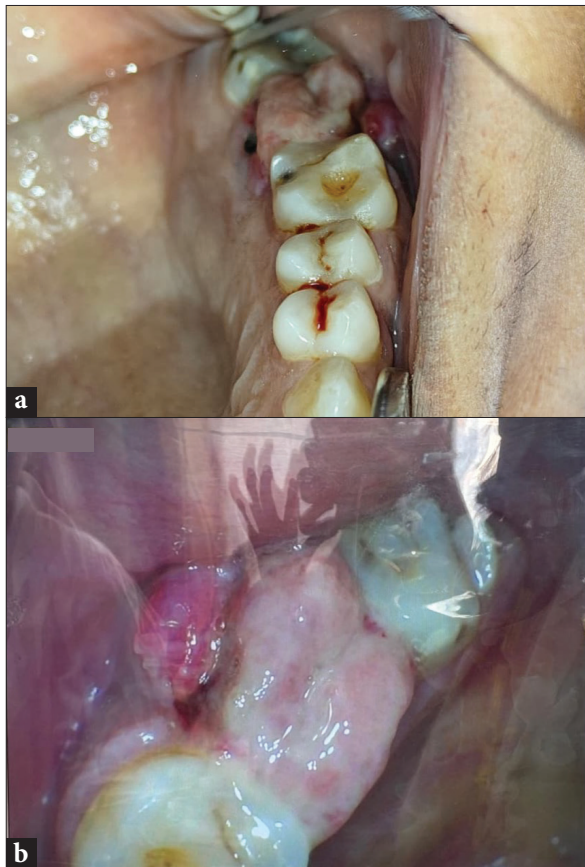


Figure 1: (a) Preoperative intraoral view showing a dark red, pedunculated gingival mass in the maxillary left posterior region with a tooth-like appearance. (b) Closer intraoral view demonstrating the pedunculated gingival lesion arising from the interdental gingiva.

Table 1: Timeline	
Time Point	Clinical Event
6–8 weeks prior to presentation	Patient noticed a small gingival swelling with intermittent bleeding during brushing
4 weeks prior	Gradual increase in size; bleeding episodes became more frequent
Initial Presentation (Day 1)	Clinical examination performed; lesion measured approximately 9 × 11 mm; provisional diagnosis made; differential diagnoses considered
Day 1	Decision for 445nm visible blue diode laser excision based on the vascular nature of the lesion and the gravid status
Day 1	Laser excision performed using a 445 nm visible blue diode laser; specimen sent for histopathological analysis
1 Week Postoperative	Mild discomfort reported; satisfactory healing; no signs of infection
2 Weeks Postoperative	Continued soft tissue maturation; no bleeding; good contour adaptation
1 Month Postoperative	Uneventful healing; no clinical evidence of recurrence (short-term follow-up)

Diagnostic assessment

Intraoral periapical radiography was performed with appropriate radiation protection measures and adherence to the as low as reasonably achievable (ALARA) principle.^[9] The radiograph revealed a submerged root stump of tooth 27, with no evidence of calcification within the soft-tissue mass [Figure 2]. Based

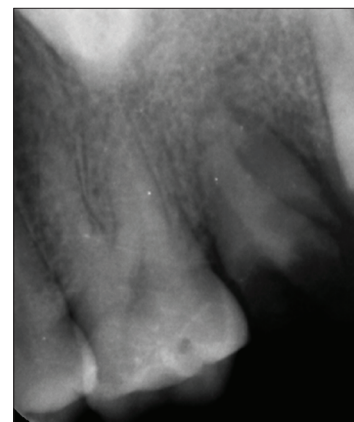


Figure 2: Intraoral periapical radiograph revealing a submerged root stump of tooth 27, with no evidence of calcification within the soft tissue lesion.

on the clinical features and patient history, a provisional diagnosis of pyogenic granuloma gravidarum was made. The differential diagnoses included peripheral ossifying fibroma, peripheral giant cell granuloma, hemangioma, irritation fibroma, and, less likely, Kaposi’s sarcoma or squamous

cell carcinoma. The absence of radiographic calcifications within the lesion makes peripheral ossifying fibroma less likely. While no evidence of underlying bone resorption reduced the likelihood of peripheral giant cell granuloma, the clinical history of rapid growth during pregnancy and the highly vascular appearance favored a diagnosis of pyogenic granuloma gravidarum. The definitive diagnosis was established through histopathological examination following excision.

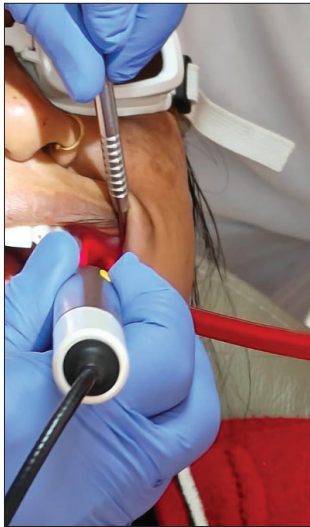


Figure 3: Intraoperative view demonstrating excision of the lesion using a 445-nm visible blue diode laser in contact mode.

Therapeutic intervention

Following a comprehensive clinical evaluation and interdisciplinary consultation with the patient's obstetrician, laser-assisted excision was planned. This treatment approach was selected in view of the lesion's pronounced vascularity, the patient's gravid status, the necessity for effective intraoperative hemostasis, and the objective of minimizing surgical trauma and postoperative morbidity. Written informed consent was obtained before the procedure. After oral prophylaxis, local anesthesia (2% lignocaine with 1:200,000 epinephrine) was administered carefully. Excision was performed using a diode laser (Siro Laser Blue diode laser system, Dentsply Sirona Bensheim, Germany) with a wavelength of 445 nm operated in continuous wave mode at a power setting of 2 W. A fiber-optic tip (Easy Tip) with a diameter of 320 μm was used in controlled sweeping motions in contact mode [Figure 3] to excise the lesion circumferentially from its base. Immediate postoperative evaluation demonstrated effective hemostasis and a clean surgical field following diode laser excision [Figure 4]. The visible blue diode laser provided excellent intraoperative hemostasis, resulting in a clear surgical field and eliminating the need for suturing. The procedure was completed with minimal- operative time and no complications. The excised

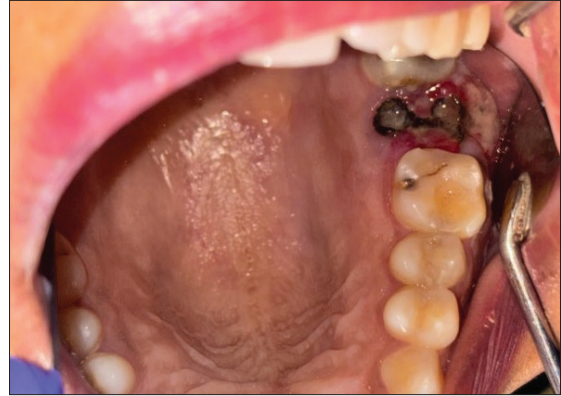

Figure 4: Immediate postoperative view showing effective hemostasis and a clean surgical field following diode laser excision.

tissue was sent for histopathological examination to confirm the diagnosis. Postoperatively, the patient was advised to follow routine oral hygiene measures and take analgesics if required [Figure 5].

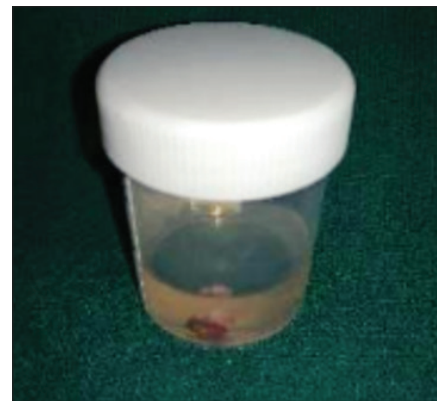

Figure 5: Excised specimen submitted for histopathological examination.

Histopathological findings

Microscopic examination revealed a parakeratinized stratified squamous epithelium exhibiting focal surface ulceration. The underlying connective tissue stroma showed highly vascular proliferation arranged in a characteristic lobular pattern. Numerous capillary-sized blood vessels of varying calibers were observed, lined with plump endothelial cells and engorged with erythrocytes. The vascular lobules were separated by delicate, fibrous septa. The intervascular stroma demonstrated dense chronic inflammatory infiltrate, predominantly composed of lymphocytes and plasma cells. No evidence of cellular atypia or malignancy was observed. These microscopic features are consistent with a diagnosis of pyogenic granuloma. The photomicrograph shown in Figure 6 is a low-power 10X magnification (H&E stain) view, highlighting the lobular arrangement of proliferating capillaries and the overall architecture of the lesion.

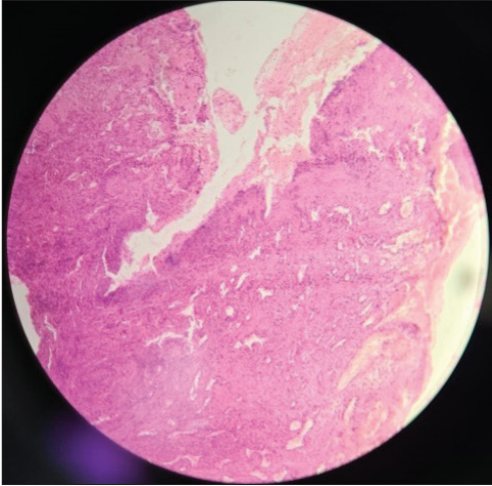


Figure 6: Histopathological photomicrograph [Hematoxylin and Eosin (H&E) stain] at low power 10X magnification showing parakeratinized stratified squamous epithelium overlying a fibrovascular connective tissue stroma with numerous capillaries and chronic inflammatory cell infiltrate, consistent with pyogenic granuloma.

Follow-up and outcomes

Postoperative healing was clinically assessed at regular intervals. The total duration of postoperative follow-up was one month. Healing was uneventful, with minimal pain, no signs of infection, and satisfactory soft-tissue contour. No evidence of lesion recurrence was observed during the follow-up period. However, a pyogenic granuloma may recur beyond this timeframe. The relatively short duration of follow-up represents a limitation of the present report, and longer-term observation is necessary to definitively assess recurrence.

DISCUSSION

The present case demonstrates the successful use of a 445 nm visible-blue diode laser for the management of pyogenic granuloma gravidarum, achieving excellent clinical outcomes with minimal invasiveness. One of the most significant advantages observed was superior intraoperative hemostasis, which is particularly beneficial in pregnant patients, where increased vascularity poses a higher bleeding risk.^[10,11] The 445 nm wavelength visible blue diode laser-assisted surgery promotes favorable wound healing through photothermal coagulation of blood vessels, resulting in reduced postoperative inflammation and edema. The formation of a superficial protein coagulum acts as a biological dressing, protecting the wound surface and reducing bacterial contamination. These effects collectively contribute to reduced postoperative pain and accelerated epithelialization compared with conventional scalpel excision.^[12,13]

In addition to hemostasis, 445 nm visible blue diode laser

excision offers reduced postoperative pain and edema due to sealing of sensory nerve endings and lymphatic vessels, along with a bactericidal effect that promotes favorable wound healing.^[14] A Study by Powell *et al.* supports the use of lasers for Pyogenic Granuloma excisions, demonstrating lower bleeding risk and improved coagulation compared to conventional techniques.^[15] Diode lasers (e.g., 808 nm, 0.1-7.0 W) are effective for intraoral Pyogenic Granuloma removal, offering ease of use and reduced recurrence, as reported by Rai *et al.*^[16] Laser gingivectomy has also been associated with lower recurrence rates than traditional methods, as reported by Mavrogiannis *et al.*^[17]

The tooth-like appearance observed clinically in this case can be explained by the pedunculated growth of the lesion from the interdental papilla and its progressive molding by adjacent teeth and functional forces, creating a pseudo-anatomical resemblance rather than an odontogenic origin. Histopathological confirmation is essential for a definitive diagnosis. Critically reflecting on this case, the absence of sutures, reduced operative time, and enhanced patient comfort highlight the clinical value of visible blue diode lasers in the management of hormonally influenced vascular lesions. However, the effectiveness of laser therapy is operator-dependent, and appropriate parameter selection is essential to avoid excessive thermal injury. While this single case demonstrates promising results with no recurrence during follow-up, larger studies and long-term evaluations are necessary to validate these findings.

Patient perspective

The patient was satisfied with the treatment outcome, reporting minimal pain, absence of bleeding after surgery, and rapid return to normal oral function.

CONCLUSION

This case report highlights the successful management of pyogenic granuloma gravidarum using a 445nm visible blue diode laser. The use of a visible blue diode laser at 445 nm enabled precise tissue excision, superior hemostasis with minimal collateral thermal damage, and rapid, uneventful healing without the need for sutures or extensive postoperative care. This approach appears to offer meaningful clinical advantages, particularly in minimizing intraoperative bleeding and patient discomfort during surgery. Nevertheless, as these findings are based on a single case, larger controlled studies are necessary to validate these outcomes and establish the comparative effectiveness of this modality relative to conventional surgical techniques.

Authors' Contributions: RKY: Conceptualization, clinical procedure, manuscript drafting; NS: Data collection, literature review, manuscript editing; NS: Corresponding

author, study supervision, case documentation, manuscript drafting, review and final approval; PV: Histopathological interpretation, critical manuscript revision.

Ethical approval: Institutional Review Board approval is not required.

Declaration of patient consent: The authors certify that they have obtained all appropriate patient consent forms. In the form, the patients have given their consent for their images and other clinical information to be reported in the journal. The patients understand that their names and initials will not be published and due efforts will be made to conceal their identity, but anonymity cannot be guaranteed.

Financial support and sponsorship: Nil

Conflicts of interest: There are no conflicts of interest.

Use of artificial intelligence (AI)-assisted technology for manuscript preparation: The authors confirm that they have used artificial intelligence (AI)-assisted technology solely for language refinement and to improve the clarity of writing. No AI assistance was employed in the generation of scientific content, data analysis or interpretation.

REFERENCES

- Hullihen SP. Case of aneurism by anastomosis of the superior maxillae. *Am J Dent Sci* 1844;4:160–2
- Regezi JA, Sciubba JJ, Jordan RCK. *Oral pathology: Clinical pathologic correlations*. 4th ed. Philadelphia: W.B. Saunders; 2003. p. 115–6
- Lomeli Martinez SM, Carrillo Contreras NG, Gómez Sandoval JR, Zepeda Nuño JS, Gomez Mireles JC, Varela Hernández JJ, *et al.* Oral pyogenic granuloma: A narrative review. *Int J Mol Sci* 2023;24:16885. doi:10.3390/ijms242316885
- Mahajan A, Singhal P, Poonam. Lobular capillary hemangioma in a child: A case report and literature review. *Open Access Sci Rep* 2012;1:265. doi:10.4172/scientificreports
- Jafarzadeh H, Sanadkhani M, Mohtasham M. Oral pyogenic granuloma: A review. *J Oral Sci* 2006;48:167–175. doi:10.2334/josnusd.48.167
- Asnaashari M, Mehdipour M, Moradi Abbasabadi F, Azari-Marhabi S. Expedited removal of pyogenic granuloma by diode laser in a pediatric patient. *J Lasers Med Sci* 2015;6:40–4.
- Iyer VH, Sasikumar R. Management of oral pyogenic granuloma with 940-nm diode laser: A rare case report. *Int J Laser Dent* 2013;3:100–104. doi:10.5005/jp-journals-10022-1046
- Gagnier JJ, Kienle G, Altman DG, Moher D, Sox H, Riley D, *et al.* The CARE guidelines: Consensus-based clinical case reporting guideline development. *Headache* 2013;53:1541–1547. doi:10.1111/head.12246
- National Council on Radiation Protection and Measurements. *Limitation of exposure to ionizing radiation*. NCRP report no. 116. Bethesda (MD): National Council on Radiation Protection and Measurements; 1993
- Sarwal P, Lapumnuaypol K. Pyogenic granuloma. In: *StatPearls* [Internet]. Treasure Island (FL): StatPearls Publishing; 2025. Available from: <http://www.ncbi.nlm.nih.gov/books/NBK556077/> [Last accessed on 2026 Jan 11]
- Saravana GH. Oral pyogenic granuloma: A review of 137 cases. *Br J Oral Maxillofac Surg* 2009;47:318–319. doi:10.1016/j.bjoms.2009.01.002
- Sachelarie L, Cristea R, Burlui E, Hurjui LL. Laser technology in dentistry: From clinical applications to future innovations. *Dent J (Basel)* 2024;12:420. doi:10.3390/dj12120420
- Kirschner RE, Low DW. Treatment of pyogenic granuloma by shave excision and laser photocoagulation. *Plast Reconstr Surg* 1999;104:1346–1369. doi:10.1097/00006534-199910000-00016
- Okumuş ÖF. Treatment of gingival growth due to amlodipine use with a 445-nm diode laser: A case report. *Cureus* 2022;14:e32592. doi:10.7759/cureus.32592
- Powell JL, Bailey CL, Coopland AT, Otis CN, Frank JL, Meyer I, *et al.* Nd:YAG laser excision of a giant gingival pyogenic granuloma during pregnancy: A case report. *Lasers Surg Med* 1994;14:178–183. doi:10.1002/1096-9101(1994)14:2<178::aid-lsm1900140211>3.0.co;2-w
- Rai S, Kaur M, Bhatnagar P. Laser: A powerful tool for treatment of pyogenic granuloma. *J Cutan Aesthet Surg* 2011;4:144–7. doi:10.4103/0974-2077.85044
- Mavrogiannis M, Ellis JS, Seymour RA, Thomason JM. The efficacy of three different surgical techniques in the management of drug-induced gingival overgrowth. *J Clin Periodontol* 2006;33:677–682. doi:10.1111/j.1600-051X.2006.00968.x

How to cite this article: Yadav RK, Singh N, Singh N, Verma P. Management of pyogenic granuloma mimicking a tooth: A Case report. *J Healthc Res Educ*. 2026;2:4. doi: 10.25259/JHRE_5_2026